



中华医学会
CHINESE MEDICAL ASSOCIATION



中华医学会神经外科学分会
CHINESE NEUROSURGICAL SOCIETY

RESEARCH

Open Access



Non-contrast CT image characteristics on admission predict the 3-month outcome of cerebral venous sinus thrombosis: an observational study in a single institution

Baoqiang Lian^{1†}, Linsun Dai^{1†}, Xueling Xie^{1†}, Dezhi Kang^{1,2†}, Guorong Chen¹, Huangcheng Shangguan¹, Peisen Yao³ and Shufa Zheng^{1*}

Abstract

Background: Various computed tomography (CT) appearances of cerebral venous sinus thrombosis (CVST) were associated with different prognosis and the patients with large intracranial hematoma will have adverse outcomes, but no in-depth study of non-contrast CT image appearances was carried out. We aimed to test the hypothesis that non-contrast CT image characteristics on admission are associated with and predict the outcome of CVST at 3 months.

Methods: Three hundred and six patients with CVST between 2008 and 2017 were collected. Age, sex, onset of CVST (acute, subacute, or chronic), etiology, clinical manifestations, midline shift, occluded venous sinus, location of infarction, non-contrast CT image characteristics, and the 3-month outcome were recorded. In addition, we established a non-contrast CT image-based classification and grading system to test the hypothesis; the CVST patients were classified into four grades (namely non-contrast CT image-based classification): grade I, no obvious abnormality; grade II, simple vein infarction without hemorrhage or with subarachnoid hemorrhage; grade III, cerebral venous infarction with subarachnoid hemorrhage; and grade IV, cerebral vein infarction with hematoma. All enrolled patients had received subcutaneous injections of low molecular weight heparin subcutaneous injection for 14 days. Thereafter, oral anticoagulant therapy with warfarin was continued. Patients with epilepsy were given antiepileptic drugs, and patients with cerebral herniation received decompressive craniotomy.

Results: Our observational findings revealed that midline shift (> 5 mm), location of lesion (frontal lobe and temporal lobe), and cerebral venous infarction with subarachnoid or hematoma (grade III and IV) were associated with 3-month poor outcome ($p < 0.05$); the respective increased risks were 12.730 [risk ratio (RR) 12.730, 95% confidence interval (CI) 1.680–96.490, $p = 0.014$], 46.538 (RR 146.538, 95% CI 6.222–348.079, $p = 0.000$), 32.549 (RR 32.549, 95% CI 2.180–486.104, $p = 0.012$), 37.725 (RR 37.725, 95% CI 2.051–693.778, $p = 0.015$), and 93.164-fold (RR 93.164, 95% CI 11.137–779.328, $p = 0.000$). However, seizure, hemiplegia, location of occluded venous sinus (super sagittal sinus and deep venous systems), location of infarction (parietal lobe), and non-contrast CT image-based classification (I) were not correlated with the adverse outcome ($p > 0.05$).

Conclusions: Our findings suggested that non-contrast CT image characteristics on admission were associated with and predict the 3-month outcome of CVST. However, the ultimate conclusions need to be confirmed by a large sample of CVST patients at multiple institutions.

Keywords: Cerebral venous sinus thrombosis, CT image characteristics, Risk factor

* Correspondence: zsf2002110@163.com

[†]Baoqiang Lian, Linsun Dai, Xueling Xie and Dezhi Kang contributed equally to this work.

¹Department of Neurosurgery, The First Affiliated Hospital of Fujian Medical University, NO. 20 Chazhong Road, Taijiang District, Fuzhou 350004, China
Full list of author information is available at the end of the article



Background

Cerebral venous sinus thrombosis (CVST) is a disorder with potentially fatal consequences, which is associated with pregnancy/puerperium, infection, cancer, autoimmune diseases, thrombotic diseases, etc., and frequently affects young and middle-aged people. Despite recent advances in the management of CVST, which include subcutaneous injection of low molecular weight heparin, infusion thrombolytic therapy with urokinase through internal carotid artery (ICA), intravenous sinus contact thrombolysis, mechanical thrombectomy, balloon dilatation, and stent angioplasty, its mortality after treatment is still up to 10% [1], especially those with venous infarction and intracranial hematoma may be more prone to develop adverse outcome. It was reported that several risk factors contributing to the poor outcome of CVST were age, Glasgow Coma Scale (GCS) scores, epileptic symptoms, substantial space occupying effect of venous infarction (with or without hemorrhage) in CT/MR images, etc [2–5].

Whether side branch circulation of occluded cerebral venous sinus was effectively established is associated with the clinical outcome. The location and numbers of the occluded venous sinus, however, did not fully predict the adverse outcome. Ferro et al.'s study showed that the large parenchymal lesions in the CVST patients predicted the poor outcome, and decompressive craniotomy should be implemented as soon as possible [6]. Many neurologists might know that various CT appearances were associated with different prognosis and CVST patients with large intracranial hematoma will have adverse outcomes, but no in-depth study of non-contrast CT image appearances was carried out. Here, we analyzed the clinical images of 306 patients with CVST in our single institution, to test the hypothesis that non-contrast CT image characteristics on admission are associated with and predict the outcome of CVST at 3 months.

Methods

All procedures performed in this observational study involving human participants were on the basis of the 1964 Helsinki declaration and approved by the ethics committee of The First Affiliated Hospital of Fujian Medical University. Informed consent was obtained from all individual participants enrolled in the study. Three hundred and six patients with CVST between 2008 and 2017 were collected. Age, sex, onset of CVST (acute, subacute, or chronic), etiology, clinical manifestations, midline shift, occluded venous sinus, location of infarction, non-contrast CT image characteristics, and the 3-month outcome were recorded. Patients were eligible for enrollment if following criteria were met: (1) the patients received brain non-contrast computed tomography (CT) scan when admitted to our institution, and

CVST were confirmed by computerized tomography venography (CTV), digital subtraction angiography (DSA), or magnetic resonance imaging (MRI) with magnetic resonance venography (MRV), (2) All enrolled patients had received subcutaneous injections of low molecular weight heparin subcutaneous injection (5000 IU, per 24 h) for 14 days. Thereafter, oral anticoagulant therapy with warfarin was continued. The dose of warfarin was adjusted to achieve a target international normalized ratio (INR 2–3). Patients with epilepsy were given antiepileptic drugs, and patients with cerebral herniation received decompressive craniotomy.

In addition, to test the hypothesis that non-contrast CT image characteristics on admission are associated with and predict the outcome of CVST at 3 months, we established a non-contrast CT image-based classification system, which represents different stages of disease. Three hundred and six CVST patients were classified into four grades (namely non-contrast CT image-based classification): grade I, no obvious abnormality; grade II, simple vein infarction without hemorrhage or with subarachnoid hemorrhage; grade III, cerebral venous infarction with subarachnoid hemorrhage; and grade IV, cerebral vein infarction with hematoma (shown in Table 1 and Fig. 1).

Statistical analysis

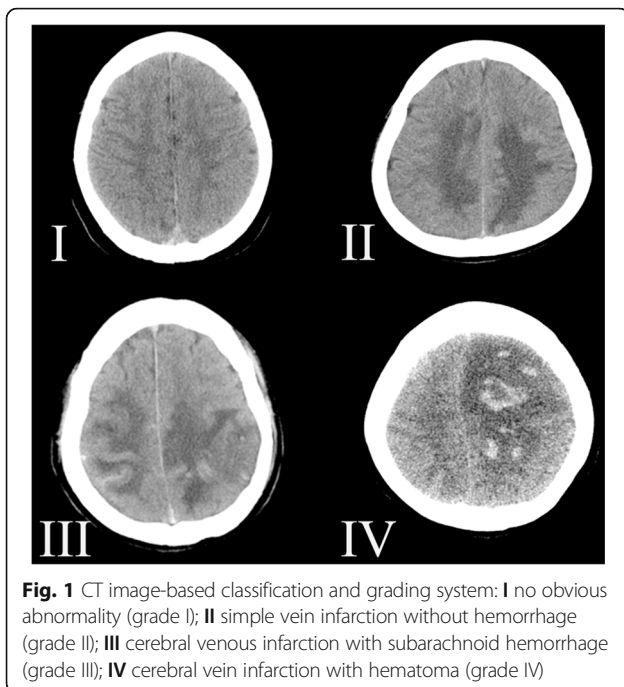
The statistical analyses were carried out using IBM SPSS version 22.0 (IBM Corp., Armonk, NY, USA). The significance differences in qualitative data were compared using a chi-squared test (χ^2 test) or Fisher's exact test. To avoid rejection of potentially important variables, all variables with significance level at $p < 0.15$ were included in multivariable analysis logistic regression analyses [7]. The receiver operating curve (ROC) was created using MedCalc 15.2.2 (MedCalc Software, Mariakerke, Belgium), to analyze the specificity, sensitivity, negative predictive values of non-contrast CT image-based classification, and positive predictive values of non-contrast CT image-based classification for Modified Rankin Scale (mRS).

Results

Three hundred and six patients were included in our observational study. The basic clinical characteristics and

Table 1 Non-contrast CT images-based classification for cerebral venous sinus thrombosis

Classification	Image characteristics of non-contrast CT
I	No obvious abnormality
II	Simple cerebral venous infarction
III	Cerebral venous infarction with subarachnoid hemorrhage
IV	Cerebral venous infarction with hematoma



radiological characteristics of CVST patients are shown in Tables 2 and 3. There was no statistical significance in the onset of CVST between the two groups ($p > 0.05$), which in our study was nearly acute and subacute (within 2 weeks) in 257/306 (84.0%). There were 249 (81.4%) patients in the good outcome group and 57 (18.6%) patients in the poor outcome group. The univariate analysis revealed there were significant differences detected in seizure, hemiplegia, GCS (3–8), midline shift (> 5 mm), the location of occluded venous sinus (super sagittal sinus and deep venous systems), the location of infarction (frontal lobe, parietal lobe, and temporal lobe), no obvious abnormality (grade I), cerebral venous infarction with subarachnoid hemorrhage (grade III), and cerebral venous infarction with hematoma (grade IV) in non-contrast CT image between favorable and poor groups ($p < 0.05$). One hundred and sixty-eight patients (54.9%) were male and 138 (45.1%) were female; the gender distribution of the two groups was not statistically significant ($p > 0.05$). There were no significant statistical differences in age, sex, onset of CVST, etiology, headache, dizziness, aphasia, visual loss, the location of occluded venous sinus (inferior sagittal sinus, straight sinus, confluence of sinuses, unilateral sigmoid/transverse sinus, bilateral sigmoid/transverse sinus, unilateral jugular vein, and bilateral jugular vein), location of infarction (occipital lobe and other), and simple cerebral venous infarction (grade II) between the two groups ($p > 0.05$) (shown in Table 3).

All variables with significance levels at $p < 0.15$ [seizure, hemiplegia, GCS (3–8), midline shift (> 5 mm),

the location of occluded venous sinus (super sagittal sinus and deep venous systems), the location of infarction (frontal lobe, parietal lobe, and temporal lobe), and cerebral venous infarction with subarachnoid hemorrhage (grade III) and cerebral venous infarction with hematoma (grade IV)] were included in multivariate logistic regression model for mRS. Our findings revealed that midline shift (> 5 mm), location of lesion (frontal lobe and temporal lobe), and cerebral venous infarction with subarachnoid hemorrhage (grade III) and cerebral venous infarction with hematoma (grade IV) were associated with 3-month poor outcome ($p < 0.05$); the respective increased risks were 12.730 [risk ratio (RR) 12.730, 95% confidence interval (CI) 1.680–96.490, $p = 0.014$], 46.538 (RR 146.538, 95% CI 6.222–348.079, $p = 0.000$), 32.549 (RR 32.549, 95% CI 2.180–486.104, $p = 0.012$), 37.725 (RR 37.725, 95% CI 2.051–693.778, $p = 0.015$), and 93.164-fold (RR 93.164, 95% CI 11.137–779.328, $p = 0.000$) (Table 4). However, seizure, hemiplegia, location of occluded venous sinus (super sagittal sinus and deep venous systems), location of infarction (parietal lobe), and non-contrast CT image-based classification (I) were not correlated with the adverse outcome ($p > 0.05$). It is noteworthy that seizure and location of occluded venous sinus (deep venous systems) exactly did not contribute to the poor outcome in our CVST patients, which is not consistent to the previous reports [5, 8].

The receiver operating characteristic (ROC) curve of non-contrast CT image-based classification is shown in Fig. 2. Predictive values of the classification for the 3-month Modified Rankin Scale (mRS) > 2 area under curve were 0.957 (95% confidence interval [CI], 0.928–0.977; $p < 0.00001$; sensitivity, 100%; specificity, 79.52%). There has been an obvious trend in the distribution of patients between the favorable and poor outcome groups according to the CT image-based classification; the proportion of patients with poor outcome is more with the increasing grade of non-contrast CT image-based classification (shown in Fig. 3).

Discussion

CVST is a fatal and disabling cerebrovascular disease, which was frequently ignored and misdiagnosed in the clinical practice because of its atypical manifestation. To date, subcutaneous injection of low-molecular-weight heparin is still the first-line treatment, because it resulted in a reduction of poor outcome and severe disability and did not promote anticoagulant-related intracranial hemorrhage. Despite recent advances in the intravascular interventional treatment, infusion thrombolytic therapy with urokinase through ICA, intravenous sinus contact thrombolysis, mechanical thrombectomy, balloon dilatation, and stent angioplasty have not significantly reduced the mortality of CVST patients.

Table 2 Basic clinical characteristics of patients with cerebral venous sinus thrombosis (CVST)

General information	Good outcome (n = 249, 81.4%)	Poor outcome (n = 57, 18.6%)	χ^2 value or Fisher's exact	P value
Age			0.444	0.505
\leq 30 years	93	24		
$>$ 30 years	156	33		
Age range (years)	15–63	14–58		
Sex			1.928	0.165
Male	132	36		
Female	117	21		
Onset of CVST			2.827	0.243
Acute	49	17		
Subacute	159	32		
Chronic	41	8		
Etiology				
Pregnancy/puerperium	18	9	0.302	0.583
Infection	9	4	1.320	0.251
Cerebral infarction	18	3	0.280	0.596
Autoimmune diseases	6	1	0.089	0.765
Thrombotic diseases	27	5	0.213	0.645
Unknown reason	33	6	0.310	0.578
Clinical manifestations			71.808	0.000
Headache, dizziness	210	45	0.970	0.325
Seizure	13	26	68.051	0.000
Hemiplegia	15	12	11.937	0.001
Aphasia	3	0	1.244	0.265
Visual loss	12	0	0.182	0.669
GCS			59.120	0.000
3–8	6	19		
9–15	243	38		
Midline shift			128.402	0.000
$<$ 0.5	243	24		
$>$ 0.5	6	33		

It is known that many risk factors could predict the clinical outcome of CVST. And it was reported that various CT appearances were associated with different prognosis and CVST patients with large intracranial hematoma will have adverse outcomes [6], but no in-depth study of non-contrast CT appearances related to CVST was carried out.

Here, we firstly tested the hypothesis that the non-contrast CT image characteristics of CVST was associated with and predicted the outcome of CVST at 3 months in our observational study. Our findings revealed that midline shift ($>$ 5 mm) and location of lesion (frontal lobe and temporal lobe) were associated with 3-month poor outcome, while GCS (3–8) was not, which was reported that it was associated with the poor outcome of CVST [2, 3, 9] and maybe be related to our

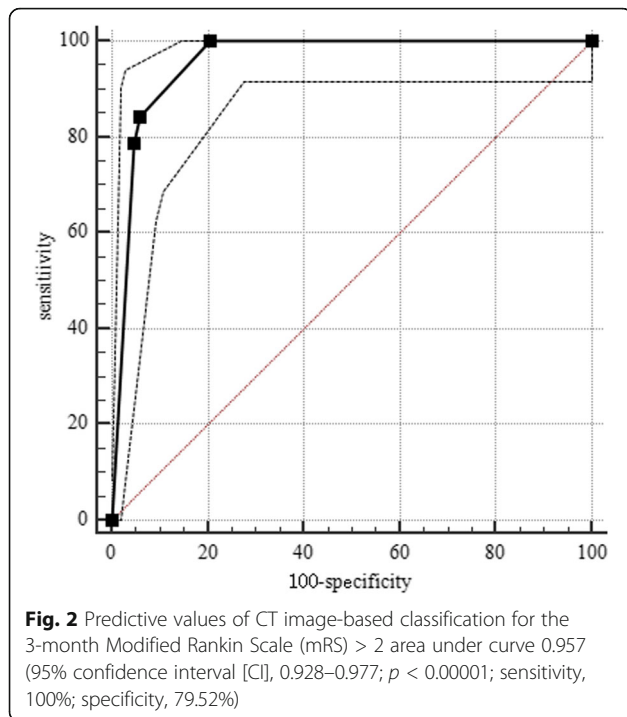
small number of our patients with poor outcome. Several previous reports, however, revealed that midline shift could result in poor outcome only when it was equal to or greater than 10 mm [10, 11], and cerebral herniation was the main cause of acute death in CVST patients. Emergent decompressive craniotomy should be performed [2]. Remarkably, we found that midline shift of $>$ 5 mm would be able to cause the adverse prognosis in CVST, which was an independent risk factor which contributed to the poor outcome. It was revealed in our study that the vein infarction located in frontal lobe would be prone to cause central herniation and partially explained the mechanism why midline shift of $>$ 5 mm would be able to cause the adverse prognosis in CVST. And it was also revealed that the vein infarction located

Table 3 Radiological characteristics of patients with CVST

General information	Good outcome (n = 249, 81.4%)	Poor outcome (n = 57)	χ^2 value	P value
Occluded venous sinus			10.879	0.209
Super sagittal sinus	168	48	6.261	0.012
Inferior sagittal sinus	12	3	0.019	0.889
Straight sinus	81	15	0.832	0.362
Confluence of sinuses	27	6	0.005	0.945
Unilateral sigmoid/transverse sinus	189	39	1.367	0.242
Bilateral sigmoid/ transverse sinus	63	18	0.939	0.332
Deep venous systems	18	0	4.378	0.036
Unilateral jugular vein	9	3	0.335	0.563
Bilateral jugular vein	6	0	1.401	0.237
Location of infarction			19.365	0.001
Frontal lobe	24	42	112.446	0.000
Parietal lobe	21	9	2.838	0.092
Temporal lobe	6	9	17.812	0.000
Occipital lobe	138	36	1.132	0.287
Other	3	1	3.974	0.742
Non-contrast CT image-based classification				
I	198	0	128.421	0.000
II	32	9	0.345	0.577
III	3	3	3.977	0.046
IV	16	45	152.839	0.000

Table 4 Predictors for poor outcome of CVST in multivariate model

Independent Variable	OR	Unadjusted		OR	Adjusted	
		OR (95% CI)	P value		OR (95% CI)	P value
Clinical manifestations						
Seizure	11.345	5.408–23.802	0.000	2.732	0.691–10.796	0.152
Hemiplegia	4.160	1.826–9.478	0.001	2.502	0.255–24.499	0.431
GCS (3–8)	23.625	8.934–62.475	0.000	0.210	0.30–1.476	0.117
Midline shift (> 0.5 mm)	55.687	21.202–146.266	0.000	12.730	1.680–96.490	0.014
Occluded sinus						
Super sagittal sinus	2.571	1.203–5.497	0.015	0.220	0.029–1.662	0.142
Deep venous systems	0.000	0.000	0.998	1.086	0.000	1.000
Location of infarction						
Frontal lobe	26.250	12.722–54.164	0.000	46.538	6.222–348.079	0.000
Parietal lobe	2.036	0.878–4.718	0.097	0.612	0.076–4.933	0.644
Temporal lobe	7.594	2.583–22.325	0.000	32.549	2.180–486.104	0.012
Non-contrast CT image-based classification						
I	0.000	0.000	0.994	0.000	0.000	0.996
III	4.556	0.895–23.186	0.068	37.725	2.051–693.778	0.015
IV	74.062	31.300–175.247	0.000	93.164	11.137–779.328	0.000



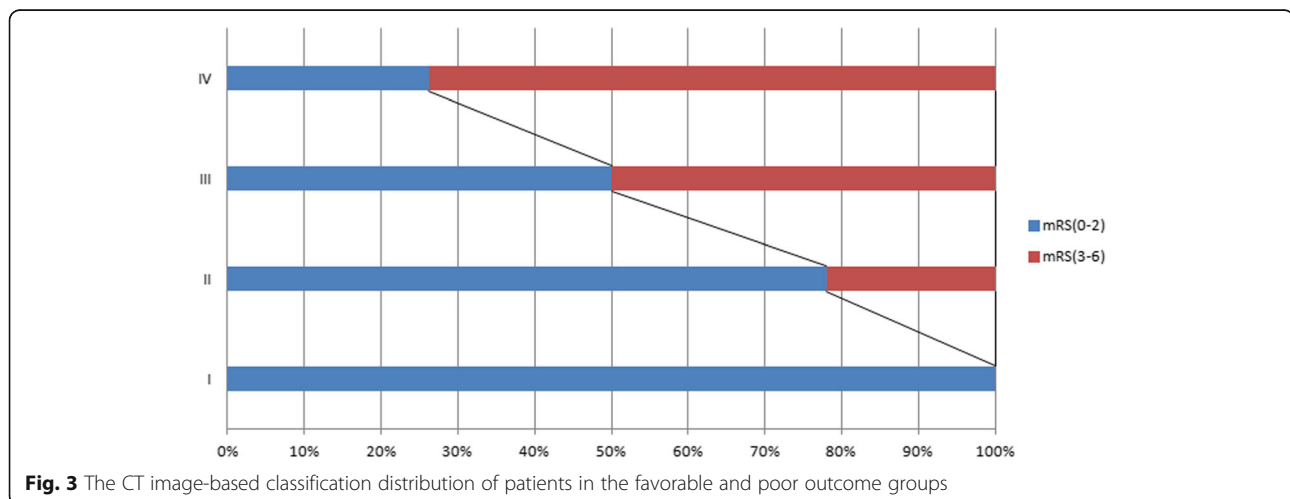
in temporal lobe contributed to the adverse outcome, which would be prone to cause transtentorial herniation.

Interestingly, we also found that cerebral venous infarction with subarachnoid hemorrhage (grade III) and cerebral venous infarction with hematoma (grade IV) were independent risk factors which contribute to the 3-month poor outcome, while grade I (no obvious abnormality) and grade II (simple venous infarction) did not. Therefore, it was deduced that grade I in the non-contrast CT image-based classification was not associated with adverse outcome in CVST and grade II was exactly the brink of

prognosis, which was the watershed to distinguish what was the risk factor. The ROC curve and the distribution of patients between the favorable and poor outcome groups according to the CT image-based classification strongly revealed that the non-contrast CT image characteristics were associated with the outcome of CVST. Non-contrast CT image-based classification was a useful tool for predicting the outcome of CVST at 3 months.

It was reported that age > 37 years and female have a much better prognosis than males [3, 12]. Nevertheless, we found that there were no significant statistical differences in age and sex between the good outcome and poor outcome groups in the univariate analysis ($p > 0.05$). Therefore, age and sex were not the risk factors contributing to poor outcome of CVST. On the contrary, we found seizure and location of occluded venous sinus (super sagittal sinus, unilateral sigmoid/transverse sinus, and deep venous systems) were not correlated with the adverse outcome ($p > 0.05$). It was reported that seizure was independently associated with supratentorial lesion; however, seizures did not correlated with the poor outcome of CVST, which is consistent with previous studies [13, 14], which cannot be fully explained by our data and not consistent with previous reports, because the number of our poor outcome group was small. Hence, the ultimate conclusions need to be further confirmed by a large sample of CVST patients.

Here, we assumed that non-contrast CT image classification was associated with the degree of sinus thrombosis of CVST, which would predict the outcome of CVST. To our best knowledge, it is the first time that the non-contrast CT classification of CVST was described. Interestingly, it was demonstrated that there has been an obvious trend in the distribution of patients with adverse/good outcome according to the CT image-based classification, and the proportion of patients with



poor outcome was more with the increasing grade of non-contrast CT image-based classification.

Limitation

Our study has its limitations: (1) It is an observational study with sample selection bias at our single institution, and the number was small. (2) The non-contrast CT image was collected on admission, which was immediate image findings and cannot reflect the dynamic changing process of CVST, especially those deteriorated after admission. (3) It is possible that the mortality of the CVST patients with grade 2–3 will be reduced with the development of drugs and interventional techniques in the future. Hence, our conclusions would be revised or be overturned.

Conclusions

Our findings revealed that midline shift (> 5 mm), location of lesion (frontal and temporal lobe), cerebral venous infarction with subarachnoid hemorrhage (grade III), and cerebral venous infarction with hematoma (IV) were independent risk factors which contribute to the 3-month poor outcome, while no obvious abnormality (grade I) and simple cerebral venous infarction (grade II) in non-contrast CT image did not. Therefore, non-contrast CT image characteristics on admission were associated with and predict the 3-month outcome of CVST. However, the ultimate conclusions need to be confirmed by a large sample of CVST patients at multiple institutions.

Abbreviations

CT: Computed tomography; CTA: Computed tomography angiography; CTV: Computerized tomography venography; CVST: Cerebral venous sinus thrombosis; DSA: Digital subtraction angiography; GCS: Glasgow Coma Scale; ICA: Internal carotid artery; MRI: Magnetic resonance imaging; mRS: Modified Rankin Scale; MRV: Magnetic resonance venography; ROC: Receiver operating curve; RR: Risk ratio

Acknowledgements

Not applicable.

Authors' contributions

LBQ, DLS, XLX, and DZK conceived of the study, participated in its design, performed the statistical analysis, and drafted the manuscript. LBQ, DLS, and DZK participated in the supervision. SFZ and PSY conceived of the study and participated in its design, coordination, supervision, and revision of the manuscript. All authors read and approved the final manuscript.

Funding

The study was supported by the Young and Middle-aged Backbone Key Research Project of the National Health and Family Planning Commission of Fujian Province (No. 2017-ZQN-46 to Pei-Sen Yao), Natural Science Funding of Fujian Province (No. 2018 J01175 to Pei-Sen Yao and No. 2018 J01176 to Shu-Fa Zheng), Key Clinical Specialty Discipline Construction Program of Fujian, P.R.C, and major project of Fujian Provincial Department of Science and Technology (No. 2014YZ0003 and No. 2014YZ01 to De-Zhi Kang).

Availability of data and materials

The datasets used and/or analyzed during the current study available from the corresponding author on reasonable request.

Ethics approval and consent to participate

The study was approved by the ethics committee of The First Affiliated Hospital of Fujian Medical University (reference number 2017079). All patients provided written informed consent.

Consent for publication

All patients in this report have formally agreed to publish their clinical information and clinical data.

Competing interests

The authors declare that they have no competing interests.

Author details

¹Department of Neurosurgery, The First Affiliated Hospital of Fujian Medical University, NO. 20 Chazhong Road, Taijiang District, Fuzhou 350004, China.

²Institute of Neurology, The First Affiliated Hospital of Fujian Medical University, NO. 20 Chazhong Road, Taijiang District, Fuzhou 350004, China.

³The First Clinical Medical College of Fujian Medical University, NO. 20 Chazhong Road, Taijiang District, Fuzhou 350004, China.

Received: 29 March 2019 Accepted: 11 June 2019

Published online: 16 July 2019

References

- de Bruijn SF, Stam J. Randomized, placebo-controlled trial of anticoagulant treatment with low-molecular-weight heparin for cerebral sinus thrombosis. *Stroke*. 1999;30(3):484–8.
- Canhao P, Ferro JM, Lindgren AG, Bousser MG, Stam J, Barinagarrementeria F. Causes and predictors of death in cerebral venous thrombosis. *Stroke*. 2005;36(8):1720–5.
- Ferro JM, Canhao P, Stam J, Bousser MG, Barinagarrementeria F. Prognosis of cerebral vein and dural sinus thrombosis: results of the International Study on Cerebral Vein and Dural Sinus Thrombosis (ISCVT). *Stroke*. 2004;35(3):664–70.
- Ferro JM, Canhao P, Bousser MG, Stam J, Barinagarrementeria F. Early seizures in cerebral vein and dural sinus thrombosis: risk factors and role of antiepileptics. *Stroke*. 2008;39(4):1152–8.
- Mahale R, Mehta A, John AA, Buddaraju K, Shankar AK, Javali M, Srinivasa R. Acute seizures in cerebral venous sinus thrombosis: what predicts it? *Epilepsy Res*. 2016;123:1–5.
- Ferro JM, Crassard I, Coutinho JM, Canhao P, Barinagarrementeria F, Cucchiara B, Derex L, Lichy C, Masjuan J, Massaro A, et al. Decompressive surgery in cerebrovenous thrombosis: a multicenter registry and a systematic review of individual patient data. *Stroke*. 2011;42(10):2825–31.
- Sun GW, Shook TL, Kay GL. Inappropriate use of bivariable analysis to screen risk factors for use in multivariable analysis. *J Clin Epidemiol*. 1996;49(8):907–16.
- Davoudi V, Keyhanian K, Saadatnia M. Risk factors for remote seizure development in patients with cerebral vein and dural sinus thrombosis. *Seizure*. 2014;23(2):135–9.
- Pfefferkorn T, Crassard I, Linn J, Dichgans M, Boukobza M, Bousser MG. Clinical features, course and outcome in deep cerebral venous system thrombosis: an analysis of 32 cases. *J Neurol*. 2009;256(11):1839–45.
- Zuurbier SM, Coutinho JM, Majoie CB, Coert BA, van den Munckhof P, Stam J. Decompressive hemicraniectomy in severe cerebral venous thrombosis: a prospective case series. *J Neurol*. 2012;259(6):1099–105.
- Aaron S, Alexander M, Moorthy RK, Mani S, Mathew V, Patil AK, Sivadasan A, Nair S, Joseph M, Thomas M, et al. Decompressive craniectomy in cerebral venous thrombosis: a single centre experience. *J Neurol Neurosurg Psychiatry*. 2013;84(9):995–1000.
- Coutinho JM, Ferro JM, Canhao P, Barinagarrementeria F, Cantu C, Bousser MG, Stam J. Cerebral venous and sinus thrombosis in women. *Stroke*. 2009;40(7):2356–61.
- Kalita J, Chandra S, Misra UK. Significance of seizure in cerebral venous sinus thrombosis. *Seizure*. 2012;21(8):639–42.
- Ferro JM, Correia M, Rosas MJ, Pinto AN, Neves G. Seizures in cerebral vein and dural sinus thrombosis. *Cerebrovasc Dis*. 2003;15(1-2):78–83.